Ennovate FRI Expert Report

Prone anterior compression correction technique using Ennovate FRI for diffuse idiopathic skeletal hyperostosis (DISH)

Kawasaki Medical School
Department of Orthopedic Surgery

Kazuo Nakanishi, MD
Kazuya Uchino, MD

Spine

B|BRAUN
SHARING EXPERTISE

Prone anterior compression correction technique using Ennovate FRI for diffuse idiopathic skeletal hyperostosis (DISH)

Kawasaki Medical School
Department of
Orthopedic Surgery
Kazuo Nakanishi, MD



Kawasaki Medical School
Department of
Orthopedic Surgery
Kazuya Uchino, MD

Diffuse idiopathic skeletal hyperostosis (DISH) is common in elderly people and can cause fractures even after minor trauma.[1,2] In addition, the fracture of DISH causes the delayed neuropathy, when it is left in the so-called 3 column injury. Since the conservative treatment is difficult, and the deterioration of neurological symptoms can occur even if the conservative treatment is carried out firmly, it becomes in which it becomes the importance that early detection and if it is possible, the fusion operation should be carried out early.[3]

Though the posterior fixation is common for the operation of the fracture with DISH, the instability of the fracture part is very strong, and in the operation of the usual prone position, bone defect and transposition by the opening of the fracture front are generated, and the possibility of exacerbation of the neurological symptom and bone nonunion is feared in.[4, 5] And there is a case in which the transposition progresses in the case in which the time has passed since it was missed, and the large bone defect has already been produced in the front. Anterior surgery is required in such cases. Recently, the following are observed: Minimally invasive surgical method using the percutaneous pedicle screw (PPS) for the fracture of DISH, insertion method which obtains the rigid fixation force for the vertebral body of the fragile DISH by penetrating intervertebral disk and endplate, report of the correction and fixation method in the lateral decubitus position, report which uses the robot in the lateral decubitus position and inserts the screw, etc..[6, 7, 8, 9, 10, 11]

Especially, the prophylaxis of the transposition by the position has been reported as a benefit of the operation of the lateral decubitus position, and the vertebra of DISH has ossified fusion between vertebral bodies, and the pedicle is difficult to see, and it is accompanied by the bone fragility.[10] The results of the operation in the lateral decubitus position are considered to be influenced by the proficiency of the operator, the performance of the fluoroscopy equipment and the existence of the navigation.

Therefore, we use the Ennovate FRI, which has a PolyLock mechanism that allows the head to be locked (monoaxialize) at any angle even without a rod and set screw, and perform corrective fixation surgery in the prone position, which is familiar to many spine surgeons.[12] We describe our anterior compression correction technique.

Preoperative preparation:

(1) When DISH fractures are diagnosed, the supine position may further extend the fracture part of this fracture, thus opening the fracture part or causing further fracture, which may cause not only neurological but also vascular and hyperelastic tissue injuries. It is important to keep the bed

raised at an angle of 30 degrees or more while waiting for surgery.

(2) Preoperative CT that are being imaged prior to diagnosis have already been taken in flat position, allowing to determine the extent of fracture opening. Also, grasp the degree of posterior element injury of the vertebral body by MRI (2 or 3 column injury) .

(3) Some suggests that people with DISH have a higher mortality rate in the first postoperative year.[4] Patients should be carefully monitored preoperatively for general condition and bone mineral density and other osteoporotic tests.

Surgical Technique: Prone Anterior Cracking Corrective Technique Using Implants

(1) The body position is made by using a carbon bed so that the fluoroscopy can be seen, and it is done in the prone position. Currently, in order to prevent bone defects and displacement caused by anterior expansion of the fracture site at the four fixation points, a pillow that cannot be confirmed by fluoroscopy is placed on the abdomen. It is to keep in mind that prone positioning under general anesthesia may further aggravate the dislocation because the erector spinae muscle relaxes.13 In addition, pedicle should be seen by fluoroscopy preoperatively, or the fracture should be checked for opening.

(2) Screws are inserted through small skin cuts according to MIS procedure. Corrective pedicle screws are inserted craniocaudally to the fractured vertebral body. The screws are inserted horizontally under fluoroscopy firmly into the vertebral body. Fixation of 3 vertebral bodies cranially and 3 vertebral bodies caudally is recommended when the fixation area is inserted in the trajectory of the normal PPS. When the screws are inserted with a trajectory that penetrates the end plate, the fixation force increases, and it is possible to shorten the fixation range to two vertebral bodies on the cranial side and two vertebral bodies on the caudal side.8 If the fracture is caudal to DISH and the lever arm is cranially long, it is cranial 3 vertebral body and caudal 2 vertebral body.

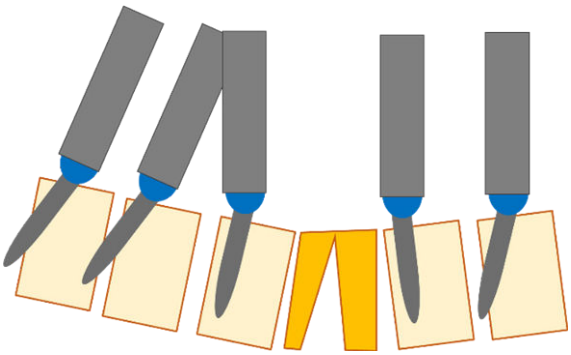

Prone anterior compression correction technique using Ennovate FRI for diffuse idiopathic skeletal hyperostosis (DISH)

(3) The rods can be inserted first or after the correction, but we prefer to insert them first. By doing so, it is possible to make the three-dimensional instability two-dimensional instability, it is possible to fasten immediately after straightening with the set screws. In addition, insertion of the rod bent to the point where it should be corrected prevents correction loss when the set screws are inserted.

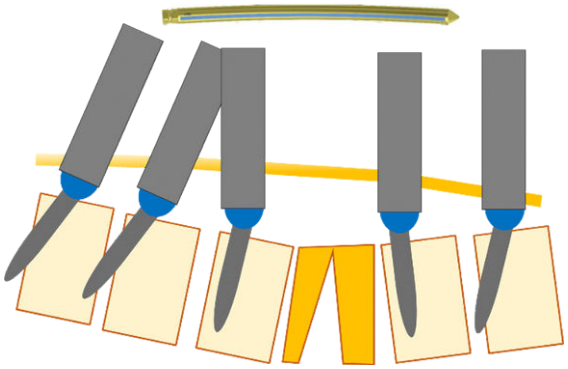

(4) Next, with the rods inserted, insert the set screws on the cranial and caudal side and temporarily fix them (the extent that it does not float up and move cranial and caudal).This ensures that the three-dimensional reduction is reduced in two dimensions and that corrective screws are not loaded during correction.

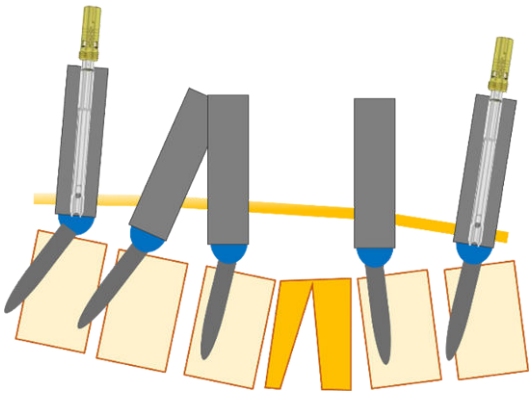

(5) Tilt down tubes by the angle to which the front opening is to be crimped.

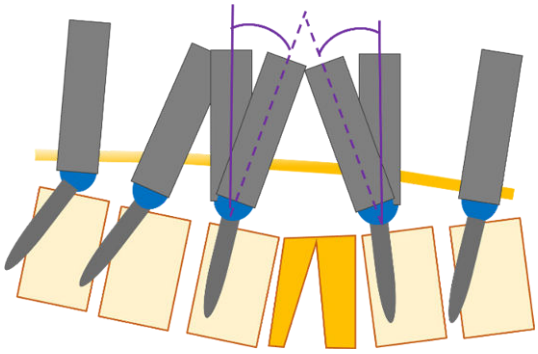

(6) PolyLock and mono-axialization of the poly-axial

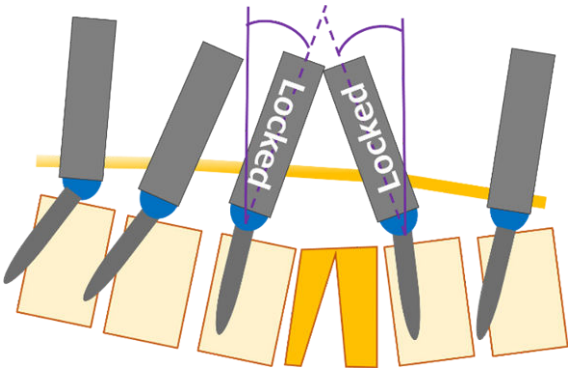

(7) Correct until the down tubes are parallel. It can be corrected by opening the extender end with a spindle, but it is important to correct it slowly while viewing fluoroscopy. DISH has weakened cancellous bone in the vertebral body, which in easy dislodgement of the screws due to the loss of corrective force.[1, 10] It is important to perform the procedure with the intention of slightly bringing the fractured parts closer together, without attempting excessive correction.



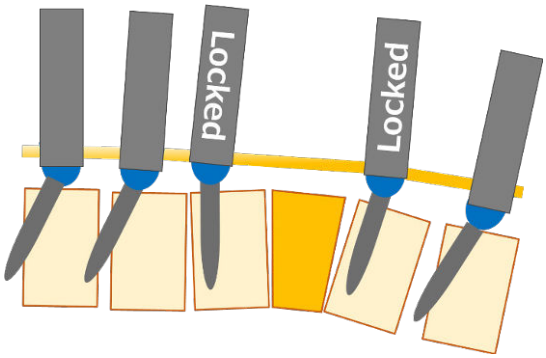

(8) Finally, the set screws are tightened and fixed.

(9) Postoperatively, the patient leaves the bed with a soft corset and is treated for osteoporosis in parallel.

Case presentation: 76-year-old woman

Preoperative plain X-ray showing fracture of the 12th thoracic vertebra

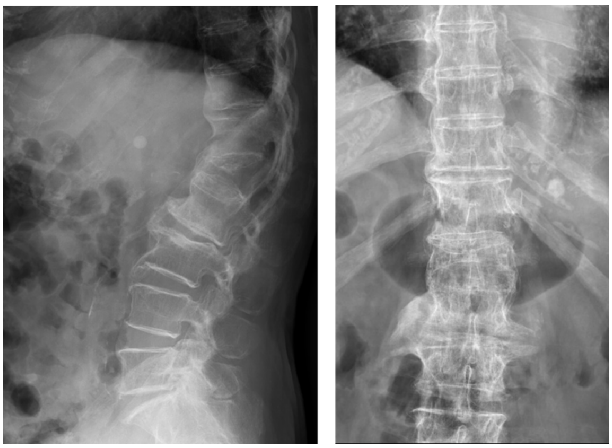

Preoperative CT:

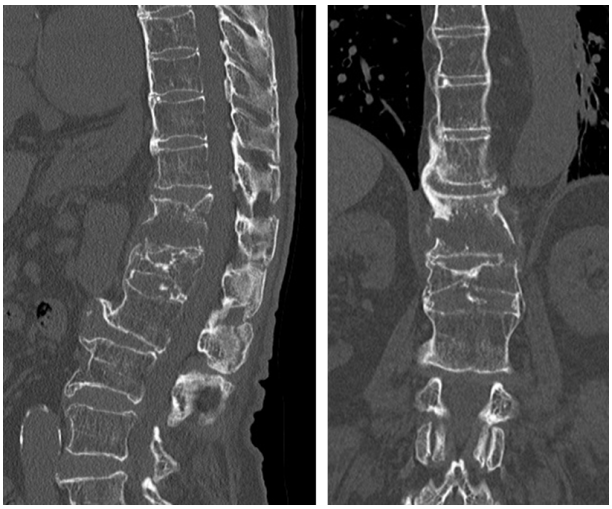

Surgical procedures were performed: 2 vertebral bodies cranially and 2 vertebral bodies caudally were fixed with MIS technique. The most cranial and most caudal screws were stabbed with the screw trajectory penetrating the endplate.

Operative time: 69 minutes, blood loss: small volume

Postoperative plain X-ray:

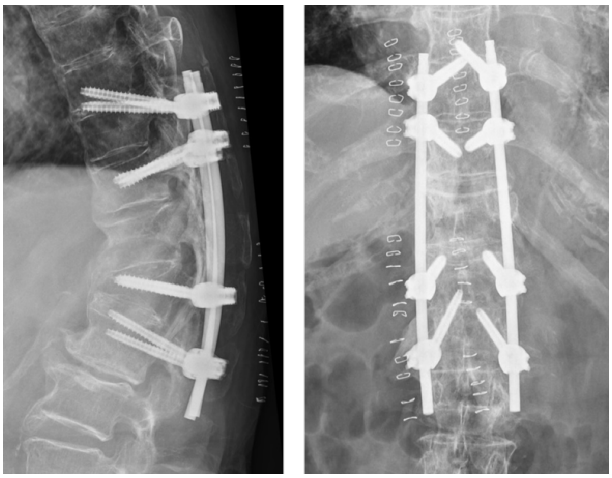

Prone anterior compression correction technique using Ennovate FRI for diffuse idiopathic skeletal hyperostosis (DISH)

Postoperative CT: The fracture was not dilated and corrected, which improved to a local angle of 11˚.

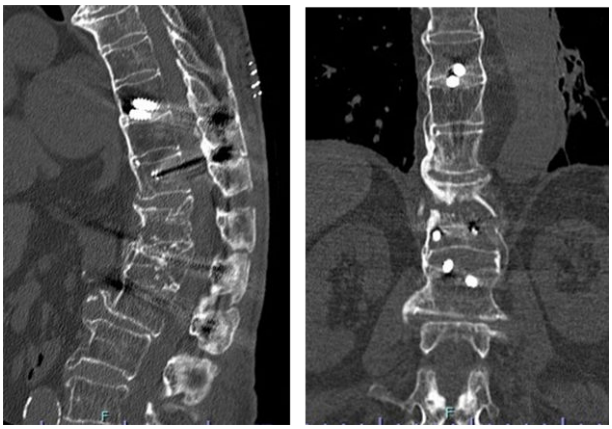

Postoperative plain X-ray (1 year after surgery) : The fracture part is bony union. No screw loosening or dislocation is observed.

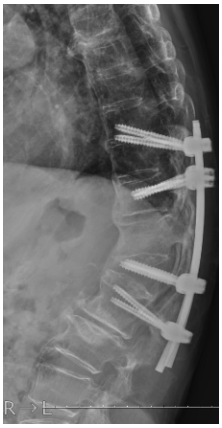

Postoperative CT images (7 months after surgery) : The fracture is already bridging and fused even at this time.

This implant was originally developed to correct kyphosis in vertebral compression fractures such as trauma.

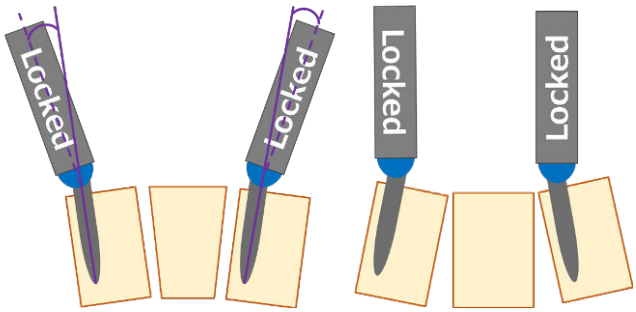

We produced a DISH bone model to verify whether the kyphotic deformity of DISH can be used for anterior compression against it, and tried it, and it was proven that the fracture part could be pressed and corrected without any problems.

DISH bone model

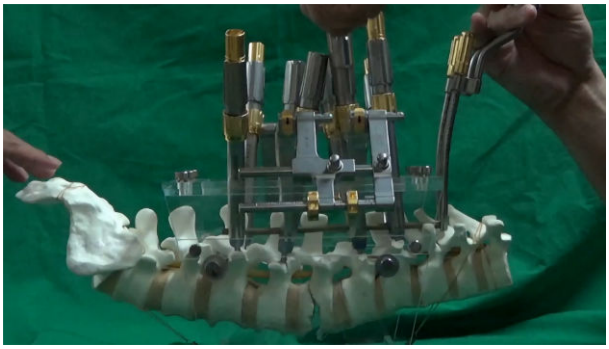

Validation experiment: Before correction



Verification experiment: After correction

The operation in the lateral decubitus position is able to compress and maintain fracture void, and the preventive effect of unintentional extension transposition of the intraoperative fracture division is expected in.9 The transposition by the position can be prevented by navigation and operator skill, and the correction in the position is also possible preoperatively. However, obscuration and bony fragility of the pedicle peculiar to the vertebral body of DISH are at-risk for deviation of guidewires and screws. On the other hand, the technique of PPS in the prone position is now common, and it is not exaggerated, even if it is said to be the basic technique of the posterior spinal operation. And the rigid fixing force can be obtained by the insertion by the screw trajectory which penetrates the endplate. In addition, Ennovate FRI can be corrected to gentle by slowly turning the spindle. It is helpful in the correction of fragile vertebrae such as DISH.

It is considered that the correction in the prone position is possible, and that the stress of the operator is reduced, and that it can be safely carried out without being influenced by the skill of the operator.

References

1. Westerveld LA, Verlaan JJ, Oner FC. Spinal fractures in patients with ankylosing spinal disorders: a systematic review of the literature on treatment, neurological status and compli cations. Eur Spine J. 2009;18:145-156. doi:10.1007/s00586 008-0764-0.
2. Eijiro Okada, Takashi Tsuji, Kentaro Shimizu. Et al. CT-based morphological analysis of spinal fractures in patients with diffuse idiopathic skeletal hyperostosis. J Orthop Sci. 2017 Jan;22(1):3-9. doi: 10.1016/j.jos.2016.09.011. Epub 2016 Oct 3.
3. Maximilian Reinhold, Christian Knop, Christian Kneit. Spine Fractures in Ankylosing Diseases: Recommendations of the Spine Section of the German Society for Orthopaedics and Trauma (DGOU). Global Spine J. 2018 Sep;8(2 Suppl):56S-68S. doi: 10.1177/2192568217736268. Epub 2018 Sep 7.
4. Troy Caron, Richard Bransford, Quynh Nguyen, et al. Spine fractures in patients with ankylosing spinal disorders. Spine (Phila Pa 1976). 2010 May 15;35(11):E458-64. doi: 10.1097/BRS.0b013e3181cc764f
5. Eijiro Okada, Kentaro Shimizu, Masanori Kato, et al. Spinal fractures in patients with diffuse idiopathic skeletal hyperostosis: Clinical characteristics by fracture level. J Orthop Sci. 2019 May;24(3):393-399. doi: 10.1016/j.jos.2018.10.017. Epub 2018 Nov 8.
6. Antonio Krüger, Michael Frink, Ludwig Oberkircher, et al. Percutaneous dorsal instrumentation for thoracolumbar extension-distraction fractures in patients with ankylosing spinal disorders: a case series. Spine J. 2014 Dec 1;14(12):2897-904. doi: 10.1016/j.spinee.2014.04.018. Epub 2014 Apr 24.
7. Cara L Sedney, Scott D Daffner, Abimbola Obafemi-Afolab, et al. A Comparison of Open and Percutaneous Techniques in the Operative Fixation of Spinal Fractures Associated with Ankylosing Spinal Disorders. Int J Spine Surg. 2016 Jun 7:10:23. doi: 10.14444/3023. eCollection 2016.
8. Ikuma H, Takao S, Inoue Y, Hirose T, Matsukawa K, Kawasaki K. Treatment of thoracolumbar spinal fracture ac companied by diffuse idiopathic skeletal hyperostosis using transdiscal screws for diffuse idiopathic skeletal hyperosto sis: preliminary results. Asian Spine J. 2 0 2 1 ;1 5 (3) :3 4 0- 3 4 8.
9. Takumi Takeuchi, Naobumi Hosogane, Kenichiro Yamagish, et al. Results of Using a Novel Percutaneous Pedicle Screw Technique for Patients with Diffuse Idiopathic Skeletal Hyperostosis-The Single or Double Endplates Penetrating Screw (SEPS/DEPS) Technique. Spine Surg Relat Res. 2020 Mar 19;4(3):261-268. doi: 10.22603/ssrr.2019-0084. eCollection 2020.
10. Hisanori Ikuma, Tomohiko Hirose, Shinichiro Takao, et al. The impact of the lateral decubitus position in the perioperative period on posterior fixation for thoracolumbar fracture with ankylosing spinal disorder. J Neurosurg Spine. 2021 Nov 26;36(5):784-791. doi: 10.3171/2021.8. SPINE21996. Print 2022 May 1.
11. Yu-Feng Shi, Zhi-Kun Shen, Bao Chen, et al. Treatment of ankylosing spondylitis with thoracolumbar fractures by robot-assisted internal fixation in lateral decubitus position. Zhongguo Gu Shang. 2022 Feb 25;35(2):113-7. doi: 10.12200/j.issn.1003-0034.2022.02.004.
12. Seiya Watanabe, Kazuo Nakanishi, Kazuya Uchino, et al. Investigation of the Usefulness of Implants With Locking Mechanisms for Diffuse Idiopathic Skeletal Hyperostosis (DISH)-Induced Thoracic and Lumbar Fractures in Patients Operated in the Prone Position. Cureus 16(8): e67071. doi:10.7759/cureus.67071.
13. Shoji H, Sawakami K, Tanaka Y, et al. Large aortic pseudoaneurysm after fusion surgery for hyperextension-type lumbar fracture in diffuse idiopathic skeletal hyperostosis: illustrative case. J Neurosurg Case Lessons. 2022, 4:2281. 10.3171/CASE2281.

AESCULAP® – a B. Braun brand

B. Braun SE | 34209 Melsungen | Germany
Phone +49 5661 71-0 | Fax +49 5661 71-4567 | www.bbraun.com

The main product trademark "AESCULAP" and the product trademarks "Ennovate", "PentaCore" and "PolyLock" are registered trademarks of Aesculap AG.

Subject to technical changes. All rights reserved. This brochure may only be used for the exclusive purpose of obtaining information about our products. Reproduction in any form partial or otherwise is not permitted.

AJOS-MKTG-data 2025.06 ARR